

Sonographic Evaluation of Carotid Artery Luminal Diameter and Degree of Stenosis in Adult Diabetic Patients in University of Maiduguri Teaching Hospital, North Eastern Nigeria

Ahmadu MS¹, Mubi BM², Adeyomoye AAO³, Ahidjo A¹, Adeyinka AO⁴, Tahir AA¹

ABSTRACT

Background: Carotid artery luminal diameter measurements have been used as clinico-radiological index of carotid artery atherosclerosis in patients with diabetes mellitus. Luminal diameter values have also been used in epidemiological and interventional studies as surrogate index of carotid atherosclerosis. However, values for luminal diameter measurements in diabetic patients are scarce in our environment.

Objectives: This study evaluates the carotid artery luminal diameter dimensions and degree of stenosis among adult diabetic patients using carotid duplex ultrasonography (CDUS).

Methods: This was a cross-sectional study carried out at the University of Maiduguri Teaching Hospital, Nigeria. One hundred and twenty adult diabetic patients aged 20 - 78 years had CDUS for measurements of carotid artery luminal diameter and degree of stenosis. Measurements were taken at 1cm below and 1cm above the carotid bulb for the common carotid (CCA) and internal carotid arteries (ICA). Pearson's correlation and Student t-test were used to compare the means between the variables.

Results: There were 72 males and 48 female diabetic patients aged 20 to 78 years (mean = 50.03±11.4 years). The mean luminal diameter, in millimeters (mm), for normal (non-stenotic) carotid arteries on the right and left were (CCA=6.58±0.52 and 6.51±0.50; ICA=4.80±0.29 and 4.79±0.31); and abnormal (stenotic) were (CCA=6.41±0.62 and 6.35±0.62; ICA=3.44±0.44 and 3.11±0.29) respectively. A total of 75 patients (62.5% of study population) had no carotid artery stenosis; 38 patients (31.7%) had <50% carotid stenosis; 6 patients (5.0%) had 50-69% carotid stenosis; and 1 patient (0.8%) had 72% carotid stenosis. The prevalence of carotid stenosis in diabetic patients was 37.5% in this study. Negative and significant correlation was noted between percentage degree of stenosis and luminal diameter ($r = -0.5$; $p < 0.05$).

Conclusion: The findings of this study have indicated the presence of atherosclerotic changes in the carotid arteries of adult diabetic patients in our environment who are at risk of developing stroke from carotid stenosis. CDUS has proved to be a valuable diagnostic and screening tool in the evaluation of these patients because of its safety, low cost, wide availability, and accuracy in detecting carotid artery disease.

Key words: carotid artery, luminal diameter, stenosis, diabetes mellitus

Department of:

¹Radiology, University of Maiduguri Teaching Hospital, Maiduguri, Nigeria

²Internal Medicine, University of Maiduguri Teaching Hospital, Maiduguri, Nigeria

³Radiodiagnosis, Lagos University Teaching Hospital, Lagos, Nigeria

⁴Radiology, University College Hospital, Ibadan, Nigeria

Corresponding Author:

Dr. Ahmadu Muhammad Sani

Department of Radiology,

University of Maiduguri Teaching Hospital,

PMB 1414, Maiduguri, Borno State, Nigeria.

Phone: +234 705 588 2425

Email: drahadums@unimaid.edu.ng

Access this article online

Quick Response Code	
	website: www.bornomedicaljournal.com
	DOI: 10.31173/bomj.bomj_94_15

Introduction

Diabetes Mellitus (DM) is a well-known modifiable risk factor for cardiovascular diseases¹, 2 and ischaemic stroke³. Diabetic patients have 2 to 5-fold increased risk for stroke compared with normal individuals²⁻⁴, and the main underlying



cause of stroke is carotid atherosclerosis^{2, 5, 6} leading to carotid stenosis¹ with most changes affecting the carotid bifurcation⁷.

Carotid arteries are the major vessels that transport oxygenated blood to the brain. Extracranial carotid artery disease is responsible for more than 50% of all strokes⁸. The ability to predict future strokes in asymptomatic patients with carotid stenosis is currently limited; therefore, identification and treatment of risk factors for stroke have become necessary over the past decade⁹. Although there is paucity of data on prevalence of diabetes in Nigeria and other African countries, available data suggest that diabetes is emerging as a major health problem in Africa, including Nigeria¹⁰. A recent study by Gezawa¹¹ reported that the prevalence of DM in Maiduguri is 7%.

Carotid duplex ultrasound (CDUS) is a non-invasive study, that does not use ionizing radiation, and it is a relatively cheap technique for evaluating the carotid arteries¹² and diagnosis of other carotid diseases¹³. This imaging modality is readily available in our environment and the data obtained from it are reproducible. CDUS uses B-mode ultrasound imaging and Doppler capability to measure the luminal diameter, blood flow velocities, and the intima media thickness (IMT) in carotid arteries¹³⁻¹⁵. It can directly visualize and assess the lumen and wall of the carotid artery¹⁶. It has also become a widely used means of detecting and characterizing carotid artery atherosclerotic disease using other sonographic parameters like peak systolic velocity (PSV) and end diastolic velocity (EDV) in the carotid arteries¹⁷.

Duplex ultrasound displays blood flow as colours superimposed on a real-time B-mode grey-scale image. The advantage of this colour-flow imaging includes the ability to rapidly identify the carotid artery and its bifurcation and any associated anatomic variations¹⁸.

Complimentary to CDUS in the assessment of carotid arterial disease are other imaging modalities including conventional angiography, magnetic resonance angiography (MRA), and contrast enhanced dynamic computed

tomography which provide an assessment of luminal size but are unable to characterize the vessel wall or associated plaques¹⁸⁻²⁰. Angiography though considered as the gold standard is an invasive procedure²¹⁻²². Moreover, conventional angiography as well as computed tomography angiography (CTA) uses ionizing radiation. Angiography, CTA and MRA are complimentary to ultrasound and have an increasing role in the evaluation of the CCA and ICA. However, their usefulness is limited by the need for sophisticated equipment and accompanying radiation exposure involved in CT and angiography. They are also expensive and may not be readily available for it to be applied to large population in a developing country.

Ultrasonographic imaging of the carotid arteries has made possible assessment of both early and advanced carotid atherosclerotic disease, in addition to its central role in many recent epidemiological studies targeted at atherosclerotic prevention trials²³.

The range of luminal diameters in normal subjects for CCA and ICA is 7 - 8mm and 4 - 6mm respectively^{14, 18}. However, other studies reported lower values for normal luminal diameters in the CCA to be in a range of 5 - 7mm^{24, 25}. The luminal diameters of the CCA and ICA is noted to decrease significantly in patients with hypertension, diabetes, and hypercholesterolaemia due to atherosclerotic changes, and are significantly smaller in women than men²⁵.

Atherosclerotic disease of the carotid arteries has long been recognized as the commonest source of emboli to the brain causing stroke^{25, 26} especially for severe atherosclerotic disease of more than 70% diameter reduction in the carotid arteries where subsequent significant vascular events occurred in 16.8% of patients²⁷.

Husni²⁸ reported that diabetes mellitus (DM) promotes atherosclerosis of the carotid arteries and may increase hypertension, hyperlipidaemia and coronary heart disease, which are also risk factors for developing stroke. Studies among Nigerians and other populations in developed countries have confirmed diabetes^{4, 29}, hypertension^{30, 31}, increasing age³²,



dyslipidaemia^{33, 34}, cigarette smoking, heavy alcohol consumption, obesity, anaemia, HIV infection and congestive cardiac failure^{29, 31, 35} as the most dominant risk factors for stroke. The identification and understanding of the magnitude of these stroke risk factors will go a long way in stroke prevention³⁶.

Diabetes mellitus has been reported to significantly increase risk of stroke following atherosclerosis of the carotid arteries⁴ and up to 20-37% of patients with stroke have been documented as diabetic²⁹. However, Noor *et al*²⁶ reported 44% of stroke patients as diabetic and said that the frequency of carotid stenosis (with involvement of right, left or both carotid arteries) as detected by duplex ultrasonography (DUS) in ischaemic stroke was 56%. But Razzaq *et al*³⁷ reported the rate of carotid stenosis in their study population to be 31%.

Olson³⁸ described a technique in 1974 depicting ultrasonography as an imaging modality to monitor the instantaneous luminal diameter, wall thickness, and blood flow of the human carotid arteries. The feasibility of using carotid ultrasonography in a large multicentre study with excellent reproducibility for evaluating the CCA and acceptable reproducibility for the ICA intima-media thickness (IMT) measurements have been reported³⁹. In measuring both the luminal diameter and the presence of stenosis, CDUS has provided a powerful non-invasive technique to determine atherosclerosis⁴⁰.

The role of CDUS as a non-invasive, frequently used imaging modality for evaluating carotid artery stenosis in patients at risk of developing carotid atherosclerosis has also been extolled by various researchers^{7, 12, 25, 39}. The results of the North American Symptomatic Carotid Endarterectomy Trial (NASCET), the European Carotid Surgery Trial (ECST), and the Asymptomatic Carotid Atherosclerosis Study (ACAS) trials have shown the importance of detecting and grading symptomatic ICA stenosis^{41, 42}.

NASCET proved conclusively the effectiveness of carotid endarterectomy in patients with symptomatic ICA stenosis greater than 70%⁴¹;

although conventional cerebral angiography was used to assess carotid stenosis in the study, the technique carries a 0.5% to 5% risk of permanent neurological deficit⁴³ and, therefore, Masatoshi⁴⁴ suggested DUS as an effective imaging modality for evaluating the presence and severity of carotid stenosis to minimize or even prevent these risks.

Holdsworth *et al*⁴⁵ noted that vascular diseases commonly occur at specific sites within the body, such as bifurcations. Carotid stenosis was seen using DUS in the region of the CCA bifurcation in 34%, 23% in proximal part of ICA and 43% in CCA²⁶. Hamid *et al*⁴⁶ reported that sonographic features of severe ICA or CCA stenosis may include PSV >230cm/sec, >50% lumen diameter reduction on greyscale image, spectral broadening, EDV >100cm/sec, and ICA/CCA PSV ratio of 4.0 or greater. Other studies found an EDV value of 110cm/sec in the carotid arteries^{12, 47}.

The increasing frequency of diabetes mellitus (and stroke as its complication) in our environment and the paucity of data on CCA and ICA luminal diameters as well as their degree of stenosis in adult diabetic patients were the justifications for this study. Additionally, the results of this study may also be used in detecting early atherosclerosis in the CCA and ICA and possibly predict clinical complications in adult diabetic patients.


Materials and Methods

Study design: This was a hospital based cross-sectional study. Subjects were recruited consecutively from the Endocrinology Unit of the Department of Internal Medicine University of Maiduguri Teaching Hospital (UMTH) based on the inclusion criteria stated below using simple random sampling until the sample size was reached.

Study area: The study was carried out at the Department of Radiology and the Endocrinology Unit of the Department of Internal Medicine, UMTH Maiduguri, Northeastern Nigeria.

Sample size estimation: This was done using Taylor's formula⁴⁸.

$$n = z^2 pq/d^2$$



Where:

n = the desired sample size (when the population is greater than 10,000)

z = the standard normal deviate, usually set at 1.96 (or more simply 2.0), which corresponds to 95 percent confidence level.

p = the proportion in the target population estimated to have a particular characteristic. The prevalence of diabetes in Maiduguri stands at 7%¹¹ (i.e. 0.07)

q = 1.0-p (i.e. 1-0.07)

d = degree of accuracy desired, usually set at 0.05

Therefore:

$$n = z^2 pq/d^2$$

$$= (2.0)^2 (0.07) (1-0.07) / (0.05)^2$$

$$= (4.0) (0.07) (0.93) / (0.0025)$$

$$= 0.26 / 0.0025$$

$$= 104$$

However, the sample size was increased to 120 to further increase the sensitivity of the study.

Study population: This study was conducted on adult male and female patients with type-2 diabetes mellitus, aged 20 years and above who met the inclusion criteria and volunteered to participate in the study. The subjects were recruited consecutively at random from the Endocrinology Unit of the Department of Internal Medicine UMTH.

Inclusion criteria: Consenting adult diabetic patients aged 20 years and above and a fasting blood glucose (FBG) of ≥ 7.0 mmol/L

Exclusion criteria: Age <20 years, pregnant patients, comorbidity of diagnosed systemic vascular disease other than diabetes mellitus and Patients with stroke or past history of cerebrovascular disease.

Methodology

The study was carried out on 120 adult type-2 diabetic patients aged 20 years and above who voluntarily participated in the study. After explaining the examination/procedure to the patient he/she was asked to wear comfortable loose-fitting clothing and remove all jewellery around the area to be examined. A brief history to

include previous cardiovascular disease was asked.

The examination was performed using a high-resolution real-time Doppler ultrasound scanner (Aloka, SSD-3500) equipped with 7.5 and 10MHz linear-array transducer. The high frequency transducer provides greater resolution for superficial structures such as the carotid artery.

With the patient in a supine position, the shoulder was placed on pillow with the neck extended and turned slightly away from the side being scanned. After applying ultrasound gel to the lateral neck, the transducer was placed above the clavicle in a transverse position initially for the grey-scale examination. The CCA was located and followed proximally as far as the clavicle permitted. The transducer was moved cephalad following the CCA to the level of the carotid bifurcation (thyroid cartilage). The internal carotid artery was then followed distally to the angle of the mandible.

The carotid luminal diameter measurements were obtained at 1cm below the carotid bulb for CCA and 1cm above the carotid bulb for ICA (Figure 1). Longitudinal and transverse views were done in B-mode (grey scale) and colour Doppler (Figures 2 and 3). A single measurement was recorded at each location for luminal diameter in the longitudinal view (Figures 3a and b), and transverse view (Figures 4a and b).

Luminal diameter was measured using B-mode (greyscale) imaging and is defined as the distance, in millimetres (mm), from the outer to the inner intima of the carotid arteries (Figures 3a and b). The normal (non-stenotic) value was taken as 6mm and 4mm for the common and internal carotid arteries respectively as reported by some researchers^{14,16, 18, 20, 45, 49, 50, 51}. The stenotic luminal diameters were calculated using the NASCET formula^{41, 42} $[1-(s/n)] \times 100$, where *s* represented the stenosed luminal diameter and *n* the suspected former luminal diameter of the carotid artery (Figure 5). Varying degrees of percentage diameter reduction were taken as values <7mm and <5mm for the CCA and ICA respectively.

Doppler interrogation of the carotid system was performed in the longitudinal plane using 60°



angle between the ultrasound beam and the vessel walls. The degree of stenosis was determined using the NASCET methodology^{41, 42} where the measured maximum flow velocity and the local narrowing in percent diameter reduction at the maximum of the stenosis were calculated according to the formula $[1-(s/n)] \times 100\%$, where s represents the tightest diameter of stenosis and n the suspected former vessel diameter (Figure 4). For the purpose of this study, the classification for degree of stenosis in CCA and ICA of the Society for Radiologists in Ultrasound (SRU) as reported by Grant *et al*⁵² was used

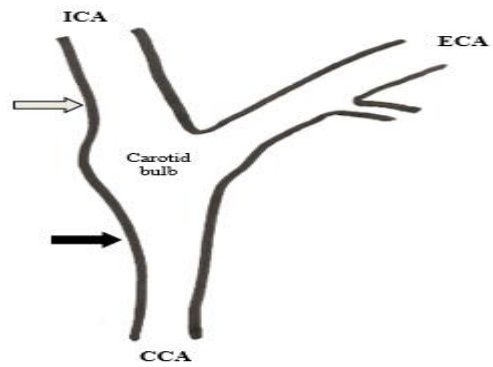


Figure 1: Points of measurements for luminal diameter and flow velocities in the CCA (black arrow) and ICA (grey arrow). ECA = External carotid artery; CCA = common carotid artery; ICA = Internal carotid artery.

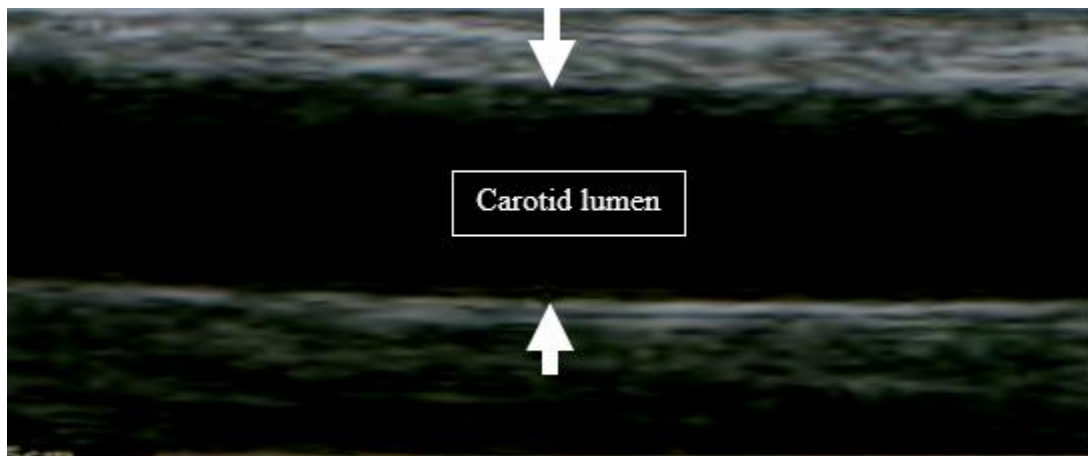


Figure 2: Greyscale ultrasonography (longitudinal view) showing method of measurement of the carotid luminal diameter in CCA and ICA.

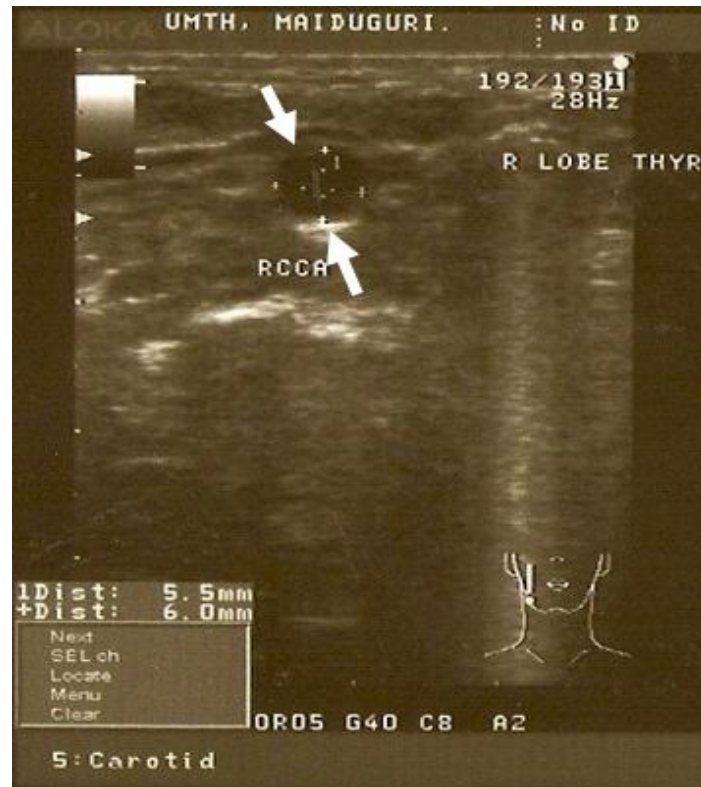

Figure 3: Transverse view grey scale ultrasonography of the right common carotid artery (RCCA) showing method of measurement of the carotid luminal diameter.

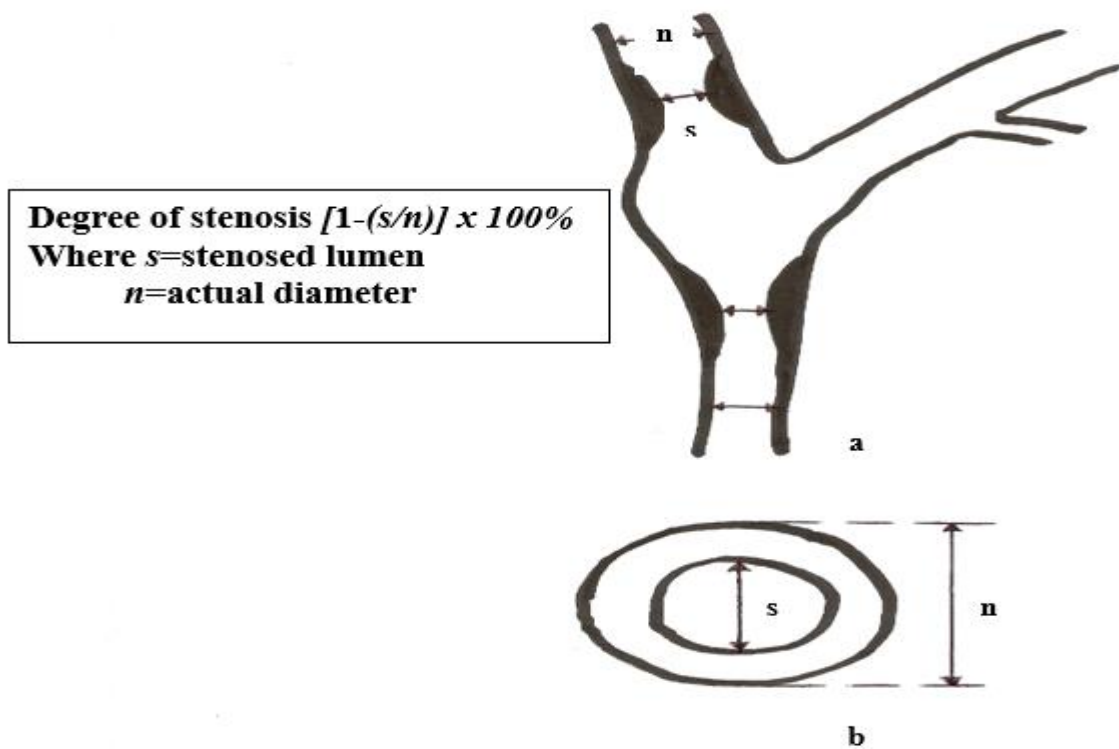


Figure 4: Method for calculating the degree of stenosis in the carotid arteries adapted from NASCET⁴¹ and Tola *et al*⁴².

Statistical analysis

The data obtained from the structured data sheet were processed and analysed using the Statistical Package for the Social Sciences (SPSS) for Windows® version 16.0 (SPSS Inc; IL, USA). The results were summarized and expressed as mean \pm standard deviation (SD) and presented in the form of tables, graphs and charts as appropriate.

Statistical significance was assessed using Students t-test (2-tailed) to compare the mean carotid artery luminal diameter and degree of carotid stenosis between the genders in the population studied. Correlation between percentage degree of stenosis with carotid artery luminal diameters was evaluated using Pearson's correlation test. *P-value* of ≤ 0.05 was considered statistically significant.

Ethical consideration

Approval to carry out the study was obtained from the Ethical Committee of the University of Maiduguri Teaching Hospital. The study was conducted with adherence to ethical standards. Informed written consent was obtained from the subjects before enlistment into the study. The

subjects were informed of the safety of ultrasound scan and could withdraw from the study at any stage without consequences. The data collected from the participants were recorded serially and kept with utmost confidentiality according to medical practice.

Results

A total of 120 adult diabetic patients aged 20 years and above were enrolled into this prospective cross-sectional hospital-based study. Seventy-two (60%) were males and forty-eight (40%) were females (Figure 5).

The age range was 20 - 78 years with a mean (\pm SD) of 50.03 \pm 11.4 years. The mean age for males was 51.97 \pm 10.39 years, while for females was 47.10 \pm 11.70 years. The predominant age group in both sexes was 40 - 49 years (35% of the total sample size) with the males having the highest frequency of 24 patients in that age group (20% of the study population). The modal age group for the study was also 40 - 49 years totalling 42 patients (35% of the total sample population) as shown in table 1.

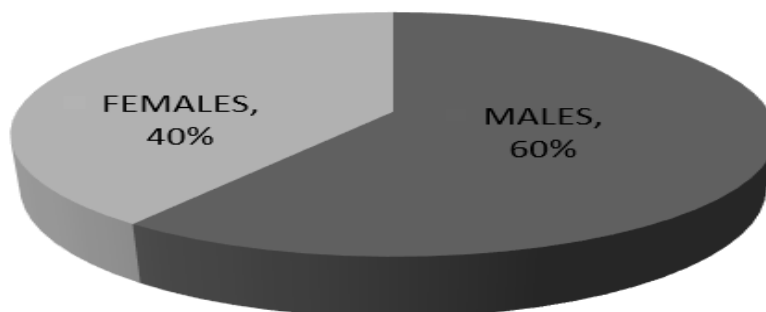



Figure 5: Pie-chart showing sex distribution of the study population

Table 1: Age-Sex Distribution pattern of study population

Age group (Years)	Males N (%)	Females N (%)	Total N (%)
20-29	2 (1.7%)	4 (3.3%)	6 (5.0%)
30-39	9 (7.5%)	9 (7.5%)	19 (15.0%)
40-49	24 (20.0%)	18 (15.0%)	42 (35.0%)
50-59	19 (15.8%)	10 (8.3%)	29 (24.1%)
60-69	14 (11.7%)	5 (4.2%)	19 (15.9%)
70-79	4 (3.3%)	2 (1.7%)	6 (5.0%)
Total	72 (60%)	48 (40%)	120 (100%)

N = Sample population



Tables 2a and 2b show the mean luminal diameters, in millimeters (mm) of the carotid arteries in the different age groups of males and females studied. The mean luminal diameters in the 40-49 years age group (42 patients; 35% of study population) were observed to be lowest in both sexes; LCCA (males=6.12±0.40mm; females=5.95±0.61mm) and LICA (males=4.72±0.87mm; females=4.29±0.62).

The highest mean luminal diameter for common carotid artery in males was noted in RCCA (6.90±0.23mm) of patients in their 8th decade while that of the internal carotid artery was seen in RICA (4.96±0.25mm) of patients aged 60-69 years. The highest mean luminal diameters in the carotid

arteries of female diabetic patients were noted in the RCCA (6.70±0.68mm) and RICA (4.97±0.66) of age brackets 60-69 years and 50-59 years respectively.

Mean luminal diameters on the right were noted to be higher than their corresponding arteries on the left. Statistical significant difference was noted between the carotid arteries on the right and left in the males in all age groups (p<0.05). However, no significant difference was observed in the right and left carotid arteries in the female patients of the study population (p>0.05). Mean luminal diameter of carotid arteries were observed to be higher in males than females in the study population

Table 2a: Age distribution pattern of luminal diameter in carotid arteries of diabetic males

LD mean±SD (mm)	20-29 yrs.	30-39 yrs.	40-49 yrs.	50-59 yrs.	60-69 yrs.	70-79 yrs.	Total
RCCA	6.43±0.95	6.37±0.32	6.31±0.46	6.48±0.66	6.86±0.54	6.90±0.23	6.56±0.53
LCCA	6.35±0.92	6.22±0.32	6.12±0.40	6.39±0.71	6.58±0.45	6.53±0.36	6.37±0.53
Total (N)	2	9	24	19	14	4	72
RICA	4.73±0.39	4.74±0.84	4.64±0.92	4.88±0.26	4.96±0.25	4.94±0.42	4.82±0.51
LICA	4.62±0.32	4.72±0.87	4.60±0.73	4.83±0.21	4.90±0.20	4.89±0.40	4.76±0.46
Total (N)	2	9	24	19	14	4	72

LD= Luminal diameter; SD = Standard deviation; RCCA= Right common carotid artery; LCCA= Left common carotid artery; RICA= Right internal carotid artery; LICA= Left internal carotid artery; N= Sample population

Table 2b: Age distribution pattern of luminal diameter in carotid arteries of diabetic females

LD mean±SD (mm)	20-29 yrs.	30-39 yrs.	40-49 yrs.	50-59 yrs.	60-69 yrs.	70-79 yrs.	Total
RCCA	6.33±0.52	6.29±0.61	6.03±0.64	6.35±0.48	6.70±0.68	6.68±0.25	6.40±0.53
LCCA	6.30±0.43	6.25±0.62	5.95±0.61	6.32±0.50	6.67±0.75	6.60±0.07	6.35±0.50
Total (N)	4	9	18	10	5	2	48
RICA	4.44±0.20	4.48±0.86	4.31±0.94	4.97±0.88	4.85±0.66	4.90±0.70	4.66±0.71
LICA	4.42±0.21	4.47±0.75	4.29±0.62	4.93±0.31	4.80±0.59	4.89±0.65	4.63±0.52
Total (N)	4	9	18	10	5	2	48

LD= Luminal diameter; SD = Standard deviation; RCCA= Right common carotid artery; LCCA= Left common carotid artery; RICA= Right internal carotid artery; LICA= Left internal carotid artery; N= Sample population



Tables 3a and b show that a total of 480 carotid arteries belonging to 120 diabetic patients were studied (120 arteries each for RCCA, LCCA, RICA, and LICA) out of which 301 carotid arteries (62.7%) were normal (0% stenosis) and 179 (37.3%) were stenotic.

The males had 110 (22.9%) stenotic carotid arteries while the females had 69 (14.4%) stenotic carotid arteries. The highest percentage stenosis was observed in LICA of a male patient. The observed range of percentage stenosis in common carotid

arteries was 0 – 36% and 0 – 72% in the internal carotid arteries.

In total, 75 patients (62.5% of study population) had no stenosis in their carotid arteries; 38 (31.7%) had <50% stenosis in their carotid arteries; 6 (5.0%) had 50-69% stenosis of carotid arteries; and 1 (0.8%) had >70% stenosis in his carotid artery (LICA). Hence, the total number of diabetic patients with varying degrees of carotid artery stenosis observed in the present study was 45 (37.5% of total study population).

Table 3a: Frequency pattern of degree of stenosis in the carotid arteries of male diabetic patients

Percentage degree of stenosis	Normal (0%)	<50%	50-69%	≥70%
RCCA	45 (37.5%)	27 (22.5%)	Nil	Nil
LCCA	44 (36.7%)	28 (23.3%)	Nil	Nil
RICA	44 (36.7%)	18 (15%)	10 (8.3%)	Nil
LICA	45 (37.5%)	15 (12.5%)	11 (9.2%)	1 (0.8%)

RCCA= Right common carotid artery; LCCA= Left common carotid artery; RICA= Right internal carotid artery; LICA= Left internal carotid artery

Table 3b: Frequency pattern of degree of stenosis in the carotid arteries of female diabetic patients

Percentage degree of stenosis	Normal (0%)	<50%	50-69%	≥70%
RCCA	31 (25.8%)	17 (14.2%)	Nil	Nil
LCCA	30 (25%)	18 (15%)	Nil	Nil
RICA	30 (25%)	10 (8.3%)	8 (6.7%)	Nil
LICA	32 (26.7%)	13 (10.8%)	3 (2.5%)	Nil

RCCA= Right common carotid artery; LCCA= Left common carotid artery; RICA= Right internal carotid artery; LICA= Left internal carotid artery

Tables 4 (a and b) and figures 6 and 7 show the relationship between percentage degree of carotid artery stenosis with carotid luminal diameter of the patients studied.

There was a negative and significant correlation between luminal diameters and percentages

degree of stenosis in carotid arteries of both sexes with < 50% and 50-69% stenosis ($r = \geq -0.5$; $p < 0.05$). No correlations were, however, observed in carotid arteries with no stenosis (normal) and ≥70% stenosis.



Table 4a: Correlation between luminal diameter and percentage degree stenosis in the carotid arteries of male diabetic patients

Luminal diameter mean±SD (mm)	Normal (0%)	<50%	50-69%	≥70%
RCCA	6.61±0.45	6.51±0.64	Nil	Nil
	<i>r= -</i>	<i>r= -0.861</i>	Nil	Nil
	<i>p= -</i>	<i>p= 0.000</i>		
LCCA	6.55±0.40	6.45±0.65	Nil	Nil
	<i>r= -</i>	<i>r= -0.942</i>	Nil	Nil
	<i>p= -</i>	<i>p= 0.000</i>		
Total(RCCA+LCCA)	45 + 44 = 89	27 + 28 = 55	Nil	Nil
RICA	4.94±0.24	4.81±0.43	2.33±0.20	Nil
	<i>r= -</i>	<i>r= -0.953</i>	<i>r= -0.963</i>	Nil
	<i>p= -</i>	<i>p= 0.000</i>	<i>p=0.000</i>	
LICA	4.89±0.25	4.72±0.52	2.46±0.36	1.85±0.00
	<i>r= -</i>	<i>r= -0.972</i>	<i>r= -0.910</i>	<i>r= -</i>
	<i>p= -</i>	<i>p=0.000</i>	<i>p=0.000</i>	<i>p= -</i>
Total(RICA+LICA)	44 + 45 = 89	18 +15 = 33	10 + 11 = 21	0 + 1 = 1

SD= Standard deviation; RCCA= Right common carotid artery; LCCA= Left common carotid artery; RICA= Right internal carotid artery


LICA= Left internal carotid artery; *r*= Correlation factor; *p*=P value

Table 4b: Correlation between luminal diameter and percentage degree stenosis in the carotid arteries of female diabetic patients

Luminal diameter mean±SD (mm)	Normal (0%)	<50%	50-69%	≥70%
RCCA	6.55±0.58	6.31±0.60	Nil	Nil
	<i>r= -</i>	<i>r= -0.934</i>	Nil	Nil
	<i>p= -</i>	<i>p=0.000</i>		
LCCA	6.46±0.59	6.24±0.59	Nil	Nil
	<i>r= -</i>	<i>r= -0.959</i>	Nil	Nil
	<i>p= -</i>	<i>p= 0.000</i>		
Total(RCCA+LCCA)	31 + 30 = 61	17 + 18 = 35	Nil	Nil
RICA	4.65±0.33	4.44±0.80	2.17±0.32	Nil
	<i>r= -</i>	<i>r= -0.665</i>	<i>r= -0.827</i>	Nil
	<i>p= -</i>	<i>p=0.036</i>	<i>p= 0.011</i>	
LICA	4.69±0.36	4.31±0.32	2.20±0.23	Nil
	<i>r= -</i>	<i>r= -0.903</i>	<i>r= -0.935</i>	Nil
	<i>p= -</i>	<i>p= 0.000</i>	<i>p= 0.02</i>	
Total(RICA+LICA)	30 + 32 = 62	10 +13 = 23	8 + 3 = 11	Nil

SD= Standard deviation; RCCA= Right common carotid artery; LCCA= Left common carotid artery; RICA= Right internal carotid artery

LICA= Left internal carotid artery; *r*= Correlation factor; *p*=P value



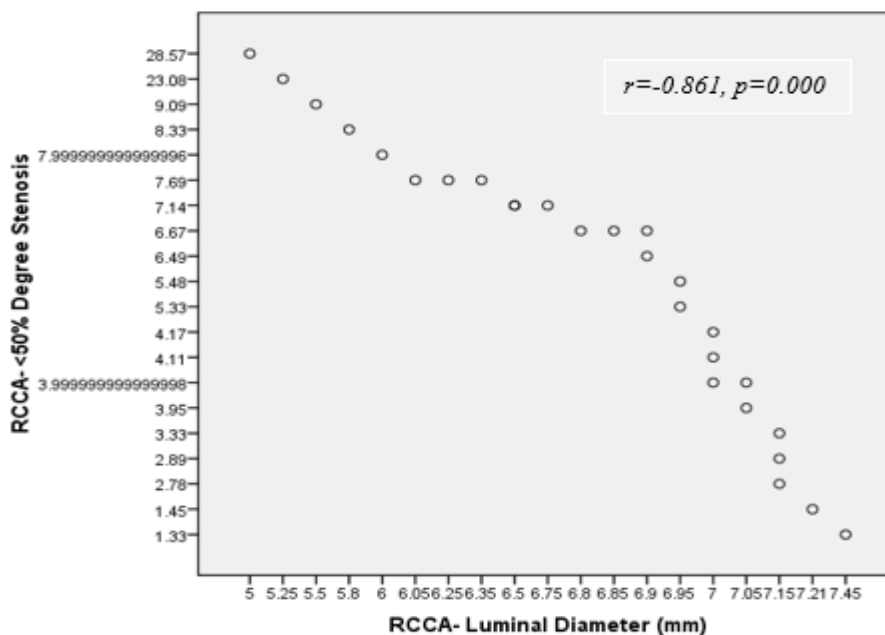


Figure 6: Scatter diagram showing a negative correlation between degree of stenosis and luminal diameter in RCCA of diabetic patients with 50%-degree stenosis.

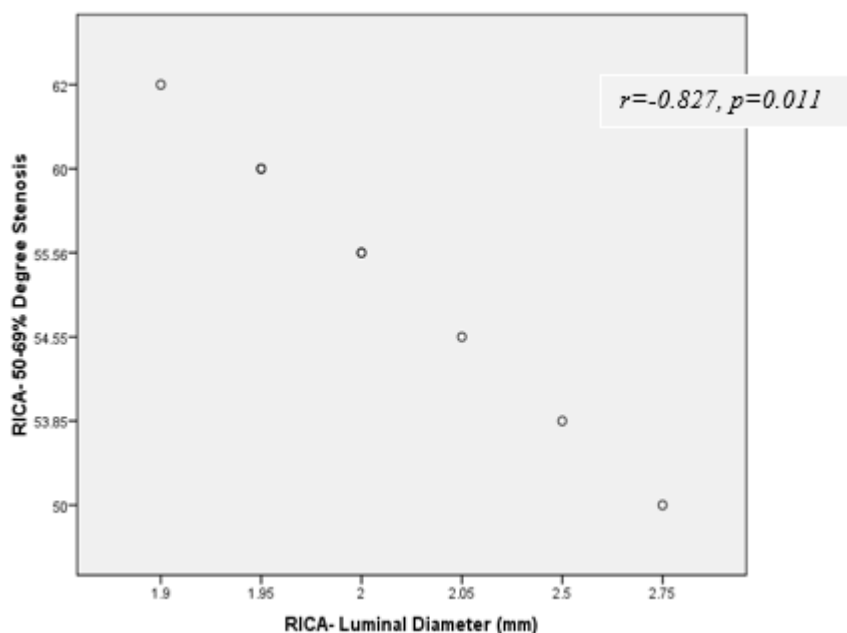



Figure 7: Scatter diagram showing a negative correlation between degree of stenosis and luminal diameter in RICA of diabetic patients with 50-69%-degree stenosis.

Discussion

Carotid arteries have been observed to be among the vessels that are prone to develop overt atherosclerotic lesions in the presence of risk factors such as diabetes mellitus and hypertension⁵³. The findings of the present study have shown that diabetes mellitus is associated with carotid artery stenosis and that ultrasonography is a

useful tool in the evaluation of these arteries in diabetic patients. Adekanmi *et al*⁵⁴ have also observed that the diagnostic value of CDUS in detecting early carotid artery lesions that may progress to stroke is important when it comes to determining the degree of carotid artery stenosis and the approach to managing such cases.



This study revealed that of the 120 diabetic patients studied aged 20 years and above with a mean age of 50.02 ± 11.4 years, a large proportion was found in the age range of 40-49 years (35% of study population). The preponderance of middle aged population in this study was because of the fact that majority of people with type 2 diabetes in developing countries are in the range of that age group. Moreover, most of the diabetic patients attending the endocrinology clinic in the study centre fall within that age group. In addition to this fact, Sara *et al*⁵⁵ in their study on the global prevalence of diabetes have also documented the increasing incidence of diabetes in these age groups due to population growth, urbanization, increasing prevalence of obesity and physical inactivity. They also reported that data on diabetes in the younger age group is limited.

In this study, a documentation of the mean luminal diameter of the common and internal carotid arteries in diabetic patients revealed that the mean luminal diameters observed in non-stenotic common carotid arteries on the right and left CCA were 6.58 ± 0.55 mm and 6.51 ± 0.99 respectively. The non-stenotic mean luminal diameters for the RICA and LICA were 4.80 ± 0.29 mm and 4.79 ± 0.31 mm respectively. The luminal diameters in the stenotic RCCA and LCCA were 6.41 ± 0.62 mm and 6.35 ± 0.62 mm respectively. Mean luminal diameter for stenotic RICA and LICA were 3.45 ± 0.45 mm and 3.11 ± 0.29 respectively. The overall mean luminal diameters in the present study were slightly lower than the values found by Huseyin *et al*⁵⁶ where they did a prospective study in a group of seventy-one Turkish diabetic adults and found their stenosed carotid artery luminal diameter to be 7.40 ± 0.79 mm, 7.13 ± 0.77 mm, 5.15 ± 0.87 mm, and 5.10 ± 0.93 mm in the RCCA, LCCA, RICA, and LICA respectively. The variation in the findings may be due to ethnic and geographical differences between the two populations studied.


The present study has observed that percentage degree of stenosis correlated negatively ($r = -0.5$; $p < 0.05$) with luminal diameters of carotid arteries in both males and females. These findings

corroborated with those of other workers who reported on carotid atherosclerosis^{1-3, 12, 15, 17, 23, 36}.

The report by the Society of Radiologists in Ultrasound (SRU) Consensus Conference in 2003^{49, 52} regarding the grading of degree of carotid artery stenosis has made the following statements: the degree of stenosis determined at grey scale and Doppler ultrasonography should be stratified into the categories of normal (no stenosis); <50% stenosis; 50-69% stenosis; $\geq 70\%$ stenosis to near occlusion; near occlusion - when there is a markedly narrowed lumen at colour Doppler USS; and total occlusion - when there is no detectable patent lumen at grey-scale US and no flow at spectral, power, and colour Doppler ultrasonography.

Doppler spectral observations made in the present study were unremarkable as majority (62.5%) of the patients with stenotic carotid arteries clustered around <50% stenosis and few (5.0%) had 50-69% carotid stenosis. In addition, some studies have shown that spectral broadening and filling of the window under the spectrum are subjective especially in carotid stenosis of <50%^{7, 12, 15, 20, 41, 57}. Moreover, carotid stenosis usually begins to show remarkable spectral waveform changes when the stenosis exceeds 70% stenosis from turbulent blood flow^{15, 20}. This was evident in this study as only the male patient with 72%-degree stenosis of the LICA had moderate spectral broadening in his Doppler waveform.

The present study adopted the stratification of carotid artery stenosis given by SRU⁵² because of its simplicity and suitability to the present study. It was observed that a total of 75 patients (62.5% of study population) had no stenosis in their carotid arteries; 38 (31.7%) had <50% stenosis in their carotid arteries; 6 (5.0%) had 50-69% stenosis of carotid arteries; and 1 (0.8%) had >70% stenosis in his carotid artery (LICA). The values of carotid luminal diameter in each of the groups of patients with the reported level of carotid stenosis were in keeping with the values given by SRU. The findings of the percentage degree stenosis were also in conformity with the findings of other researches in carotid atherosclerosis^{9, 20, 46}.



The observed prevalence of carotid stenosis in the present study was found to be 37.5% of the total study population. In a retrospective study using CDUS by Razzaq *et al*³⁷ in 45 diabetic patients diagnosed of stroke, they found carotid artery stenosis >50% in 31% of their study population. Noor *et al*²⁶ in their study of 100 patients with ischaemic infarction found 44% of the patient to be diabetic and that 56% of the diabetic patients in their study had carotid artery stenosis as detected by CDUS.

The present study and those of previous researchers^{26, 37} have, therefore, shown that diabetic patients are prone to develop carotid artery atherosclerosis that may be a cause of stenosis in these arteries. Hence, the clinical value of CDUS as an imaging modality in the management and prevention of cerebrovascular diseases, especially in diabetics, is indispensable. Therefore, the ability to quickly and efficiently identify carotid stenosis in patients at risk, using CDUS is of clinical importance. Identification of potentially treatable carotid stenosis enables selection and appropriate patients for stent implantation or carotid endarterectomy.

Conclusion

Carotid Duplex ultrasonography (CDUS) is an important imaging modality for early detection of carotid artery (CA) stenosis, especially in diabetic patients who are at risk for developing CA atherosclerosis. CDUS has established its role in screening and diagnosis of carotid artery disease because of its safety, low cost, and accuracy in detecting carotid artery disease.

The mean values of CCA and ICA luminal diameters in adult diabetic patients in this environment as well as the degree of stenosis in these arteries were determined using carotid duplex ultrasonography. The difference in the means for the observed values between males and females were found to be statistically significant.

The findings of this study have substantial implications for clinical practice and public health especially with regards to stroke prevention in adult diabetic patients. The study has, therefore, provided useful baseline data on which


subsequent radiological and clinical interventions may be based.

References

1. Lacroix P, Aboyans V, Criqui MH, Bertin F, Bouhamed T, Archaubeaud F. Type-2 Diabetes and Carotid Stenosis: A Proposal for a Screening Strategy in Asymptomatic Patients. *Vasc Med* 2006; 11:93-99.
2. Osling G, Hedblad B, Berglund G, Goncalves I. Increased Echolucency of Carotid Plaques in Patients with Type-2 Diabetes. *Stroke* 2007; 38:2074-2078.
3. Azra Z, Syed KS, Maimoona S, Farrukh SK. Pattern of Stroke in Type-2 Diabetic Subjects versus Non-Diabetic Subjects. *J Ayub Med Coll Abbottabad* 2007; 19(4):64-67.
4. Ellen LA and Brett MK. Diabetes: The Metabolic Syndrome, and Ischaemic Stroke. *Diabetes Care* 2007; 30(12):3131-3140.
5. Osuntokun BO, Adeuja AOG, Schoenberg BS. Neurological Disorders in the Nigerian Africans: A Community-based Study. *Acta Neurol Scand* 1987; 75:13-21.
6. Handa N, Masayasu M, Hiroaki M, Hidetaka H, Satoshi O, Ryuzo F, *et al*. Ultrasonic Evaluation of Early Carotid Atherosclerosis. *Stroke* 1990; 21:1567-1572.
7. Diana G, Michalle S. Diagnosing Carotid Stenosis by Sonography: State of the Art. *J Ultrasound Med* 2005; 24:1127-1136.
8. Mira LK. Carotid Duplex Imaging. At <http://www.gehealth.com/user/ultrasound/products/msucmecd.html>. Accessed on 22/12/2017.
9. Liapis CD, John DK, Alkiviadis GK. Carotid Stenosis: Factors Affecting Symptomatology. *Stroke* 2001; 32:2782-2786.
10. Nyenwe EA, Osaretin JO, Anele EI, Aaron O, Babatunde S. Type-2 Diabetes in Adult Nigerians: A Study of its Prevalence and Risk Factors in Port Harcourt, Nigeria. *Diabetes Research and Clinical Practice* 2003; 62:177-185.



11. Gezawa ID. Normative Anthropometric Values and Glucose Intolerance among Adults in Maiduguri, North-eastern Nigeria. Fellowship Dissertation submitted to the National Postgraduate Medical College of Nigeria (NPMCN), November, 2009.
12. Rebecca S. Carotid Artery Disease. In: Roger CS, Tom W. Clinical Sonography: A Practical Guide. Lippincott William & Wilkins. Baltimore 2007; Pp 535-542.
13. Tsuruda JS, Saloner D, Anderson C. Non-invasive Evaluation of Cerebral Ischemia. Trends for the 1990s. *Circulation* 1991; 83(2 Suppl):176-89.
14. Zwiebel WJ. Duplex Sonography of the Cerebral Arteries: Efficacy, Limitations and Indications. *AJR* 1992; 158:29-36.
15. Maria GMH, Joseph FP, Barlan MM, O' Leary DH. Detection and Quantification of Carotid Artery Stenosis: Efficacy of Various Doppler Velocity Parameters. *AJR* 1992; 160:619-625.
16. Masaaki S, Kazuya S, Akio K, Yasushi H, Yuichi H, Motoo T, Yutaka H. Insulin Resistance as an Independent Risk Factor for Carotid Wall Thickening. *Hypertension* 1996; 28:593-598.
17. Vivian SL, Barbara SH, Mark AK, Barbara AC. Assessment of Stenosis: Implications of Variability of Doppler Measurements in Normal Appearing Carotid Arteries. *Radiology* 1999; 212:493-498.
18. Zierler RE, David JP, Kirk WB, Primozych JF, Strandness DE. Non-invasive Assessment of Normal Carotid Bifurcation Haemodynamics with Colour-flow Ultrasound Imaging. *Ultrasound in Medicine and Biology* 1987; 13(8): 471-476.
19. Moazzam AA, Hassan A, Tariq M. Frequency of Carotid Atherosclerosis in Cerebral Infarction. *Pak J Med Sc* 2008; 24(1):69-73.
20. Paul SS. Ultrasound of the Carotid and Vertebral Arteries. *British Medical Bulletin* 2000; 56(2):346-366.
21. Zhu CZ, Norris JW. Role of Carotid Stenosis in Ischaemic Stroke. *Stroke* 1990; 21:1131-1134.
22. Mittl RL Jr, Broderick M, Carpenter JP, Goldberg HI, Listerud J, Mishkin MM, et al. Blinded-reader Comparison of Magnetic Resonance Angiography and Duplex Ultrasonography for Carotid Artery Bifurcation Stenosis. *Stroke* 1994; 25:4-10.
23. Rolf K, Kristina S, Michael H, Stephen M. Characterization of Carotid Artery Plaques Using Real-time Compound B-mode Ultrasound. *Stroke* 2004; 35:870-875.
24. The common carotid artery - Human anatomy 2007. At <http://www.theodora.com/anatomy/the-common-carotid-artery.html>. Accessed on 22/12/2017.
25. Chang YC, Lin SK, Ryu SJ, Wai YY. Common Carotid Artery Occlusion: Evaluation with Duplex Sonography. *AJNR* 1995; 16:1099-1105.
26. Noor UH, Rukhsana, Khursheed HA, Naveed I. Frequency of Carotid Artery Stenosis in Ischaemic Stroke by using Carotid Doppler Ultrasonography in a Teaching Hospital. *Gomal J Med Sci* 2009; 7(2):82-85.
27. David S, Roger HSG, Allan PL, Jeremy PRJ. Arteriography and interventional Angiography. In: David Sutton (Ed). *Textbook of Radiology and Imaging*. 7th Edition. Elsevier/Churchill Livingstone, USA 2005; Pp 461-465.
28. Husni S. Analysis of Cerebrovascular Accidents at Prince Hashem Hospital, Jordan. *JRMS* Dec 2003; 10(2):69-72.
29. Amu E, Ogunrin O, Danesi M. Re-appraisal of Risk Factors for Stroke in Nigerian Africans - A Prospective Case-control Study. *African Journal of Neurological Sciences* 2005; 2:20-27.
30. Ogungbo BI, Gregson B, Mendelow AD, Walker R. Cerebrovascular Disease in Nigeria: What Do We Know and What Do We Need to Know? *Trop Doc* 2003; 33:25-30.



31. Osuntokun BO. Stroke in Africans. *Afr J Med Sci* 1977; 6(2):39-53.
32. Bonita R, Beaglehole R, North JDK. Events, Incidence and Case-fatality Rates of Cerebrovascular Disease in Auckland, New Zealand. *Am J Epidemiol* 1984; 120:236-243.
33. Zabsonre P, Yameogo A, Millogo A, Dyemkouma FX, Durand G. Risk and Severity Factors in Cerebrovascular Accidents in West African Blacks of Burkina Faso. *Med Trop (Mars)* 1997; 57:147-152.
34. Connor M, Rheeder P, Bryer A, Meredith M, Buekes M, Dubb A, Fritz V. The South African Stroke Risk in General Practice Study. *S Afr Med J* 2005; 95:334-339.
35. Nwosu CM, Nwabueze AC, Ikeh VO. Stroke at the Prime of Life: A Study of Nigerian Africans Between the ages of 16 and 45 years. *E Afr Med J* 1992; 69:384-390.
36. Ogunrin AO. Recent Advances in the Management of Cerebrovascular Accidents. *Benin Journal of Postgraduate Medicine* 2007; 9(1):28-40.
37. Razzaq A, Khan B, Jadoon C, Baig S. Carotid Doppler Ultrasonography in Young Stroke Patients. *J Pak Med Assoc* 1999; 49:97-99.
38. Olson RM. Human Carotid Artery Wall Thickness, Diameter, and Blood Flow by Non-invasive Technique. *J Appl Physiol* 1974; 37:955-960.
39. Epidemiology of Diabetes Intervention and Complications (EDIC) Research Group. Effect of Intensive Diabetes Treatment on Carotid Artery Wall Thickness in EDIC. *Diabetes* 1999; 48:383-390.
40. Salonen R, Salonen JT. Progression of Carotid Atherosclerosis and its Determinants: A Population-based Ultrasonography Study. *Atherosclerosis* 1990; 81:33-40.
41. North American Symptomatic Carotid Endarterectomy Trial Collaborators. Beneficial Effect of Carotid Endarterectomy in Symptomatic Patients with High Grade Carotid Stenosis. *N Engl J Med* 1991; 325:445-453.
42. Tola M, Yurdakul M, Cumhur T. Combined Use of Duplex Ultrasonography and B-flow Imaging for Evaluation of Patients with Carotid Artery Stenosis. *Am J Neuroradiol* 2004; 25:1856-1860.
43. Hankey GJ, Warlow CP, Sellar RJ. Cerebral Angiographic Risk in Mild Cerebrovascular Disease. *Stroke* 1990; 21:209-222.
44. Masatoshi K, Kazumi K, Kazuo M, Takenori Y. Diagnosis of Internal Carotid Artery Stenosis Greater than 70% with Power Doppler Duplex Sonography. *Am J Neuroradiol* 2001; 22:413-417.
45. Holdsworth DW, Norley CJD, Frayne R, Steinman DA, Rutt BK. Characterization of Common Carotid Artery Blood Flow Waveforms in Normal Human Subjects. *Physiol Meas* 1999; 20:219-240.
46. Hamid RT, Anne RB, Peter LC, Cathy HF. Sonographic Examination of the Carotid Arteries. *Radiographics* 2005; 25:1561-1575.
47. Neale ML, Chambers JL, Kelly AT. Reappraisal of Duplex Criteria to Assess Significant Carotid Stenosis with Special Reference to Reports from the North American Symptomatic Carotid Endarterectomy Trial and the European Carotid Surgery Trial. *J Vasc Surg* 1994; 20:642-649.
48. Araoye MO. Research Methodology with Statistics for Health and Social Sciences. 1st edition. Nathadex Publishers, Ilorin 2004; Pp 117-119.
49. Brian S. Carotid Ultrasound. At www.emedicine.medscape.com. Accessed on 22/12/2017.
50. Stella SYH. Carotid Ultrasonography – How Do I Do It? *ASUM Ultrasound Bulletin* 2004; 7(2):11-14.
51. Pignoli P. Ultrasound B-Mode Imaging for Arterial Wall Thickness Measurement. *Atheroscler Rev* 1984; 12:177-184.
52. Grant EG, Benson CB, Moneta GL, Alexandrov AV, Baker JD, Bluth EI, *et al*.



- Carotid Artery Stenosis: Grey-scale and Doppler US Diagnosis - Society of Radiologists in Ultrasound Consensus Conference. *Radiology* 2003; 229:340-346.
53. Adaikkappan M, Sampath R, Felix AJW, Sethupathy S. Evaluation of Carotid Atherosclerosis by B-Mode Ultrasonographic Study in Hypertensive Patients compared to Non-Hypertensive Patients. *Indian J Radiol Imaging* 2002; 12(3):365-368.
54. Adekanmi AJ, Adeyinka AO, Agunloye AM. The Role of Doppler Ultrasound in the Evaluation of Carotid Occlusive Disease. *West Afr J Ultrasound* 2007; 8:1-7.
55. Sarah W, Gojka R, Anders G, Richard S, Hilary K. Global Prevalence of Diabetes: Estimation for the Year 2000 and Projection for 2030. *Diabetes Care* 2004; 27:1047-1053.
56. Huseyin O, Hakan A, Selami S, Erkin O. Effects of Overweight on Luminal Diameter, Flow Velocity and Intima media thickness of Carotid Arteries. *Diagn Interv Radiol* 2006; 12:142-146.
57. Yoshimitsu Y, Mineo K, Hideko N, Sakamoto K, Matsuhisa M, Yoshitaka K, *et al.* Carotid Intima-Media Thickness in Japanese Type 2 Diabetic Subjects: Predictors of Progression and Relation with Incident Coronary Heart Disease. *Diabetes Care* 2000; 23(9):1310-1315.

Cite this article as: Ahmadu MS, Mubi BM, Adeyomoye AAO, Ahidjo A, Adeyinka AO, Tahir AA. **Sonographic Evaluation of Carotid Artery Luminal Diameter and Degree of Stenosis in Adult Diabetic Patients in University of Maiduguri Teaching Hospital, North Eastern Nigeria. *Bo Med J* 2018;15(1): 43-58. **Source of Support:** Nil, **Conflict of Interest:** None declare**

